

# Type III Supracondylar humeral fracture in children treated by 3 lateral versus 2 cross K-wire fixation, Aden, Yemen

Abdulsalam Abdullah Hadi Mohsen<sup>1</sup>, Nazih Ali Abdulrahman Omer<sup>2</sup>,  
Mustafa Kamal Mustafa<sup>2</sup>

(1) Associate Professor, Department of Special Surgery, Faculty of Medicine, University of Aden,

(2) Assistant Professor, Department of Special Surgery, Faculty of Medicine, University of Aden.

## Correspondence:

Dr. Abdulsalam Abdullah Hadi Mohsen,  
Department of Special Surgery, Faculty of Medicine,  
University of Aden, Yemen

Email: al.ezz2007@yahoo.com

Received: October 2022 Accepted: November 2022; Published: December 1, 2022.

Citation: Abdulsalam Abdullah Hadi Mohsen, Nazih Ali Abdulrahman Omer, Mustafa Kamal. Type III Supracondylar humeral fracture in children treated by 3 lateral versus 2 cross K-wire fixation, Aden, Yemen. World Family Medicine. 2022; 20(12): 40-46. DOI:10.5742/MEWFM.2022.95251405

## Abstract

**Background:** Supracondylar fractures of humerus are the most common elbow fractures seen in children.

**Objective:** To describe the patients' condition and to evaluate the treatment and the outcome.

**Materials and method:** We retrospectively reviewed the records of 40 consecutive patients with 40 displaced, supracondylar fractures of the humerus treated between January 2019 and December 2020, in Aden.

The obtained data were sex, age, side of injury, time between injury and fixation, trial of reduction and complications.

The collected data were tabulated and statistical analysis was done by estimating rates, means and standard deviations, Fisher test was used and p-value < 0.05 was considered as statistically significant. The statistical software package SPSS version 17 was used.

**Results:** The total study patients were 40 patients. Twenty-one (52.5%) were males and 19 (47.5%) were females. The age of the patients ranged between 2 to 10 years and the mean age was 6.6 ± 2.1 years. Twenty-four (60%) had the fracture on the right arm, and 16 (40%) had it on the left arm.

All the patients underwent surgery within 24 hours of injury. The mean time was 8.1 ± 4.5 hours.

There were 11 (27.5%) cases of once trial reduction, 14 (35%) of twice trial reduction and 15 (37.5%) of three times trial reduction. The average removal of K-wires was 3.55 weeks. Twenty-six (65%) patients were treated by III lateral K-wires fixation and 14 (35%) were treated by crossed K-wire fixation.

Post-operatively, (17.5%) patients got neuropraxia in the crossed K-wire group (n = 14), and none in the III lateral K-wire group. Two (5.0%) patients got angulation, one in the crossed K-wire group (n = 14), and one in the III lateral K-wire group (n = 26). Cupitus varus were seen in 2 (5.0%) patients in the crossed K-wire group and 2 (5.0%) in the III lateral K-wire group. Stiffness was found in the III lateral K-wire group with 2 (5.0%) patients.

**Conclusion:** The delay in surgical treatment may cause a number of complications.

**Key words:** Treatment, supracondylar fracture, humerus, children, Aden

## Introduction

Supracondylar fractures of humerus are the most common elbow fractures seen in children [1,2,3,4].

Numerous studies have reported that supracondylar humeral fractures occur with nearly equal frequency among females and males [5], accounting for approximately 10% of all fractures in children [6] and 70% of all pediatric elbow injuries [7].

Omid et al [8] reported that supracondylar fractures of the humerus accounted for 55% to 80% of total elbow fractures in children and up to two-thirds of paediatric elbow injuries requiring hospitalization.

Other studies reported that supracondylar humeral fractures were most common in the first decade of life and more in males than females [9,10,11].

Some authors, however, have found no variations among the sexes whereas others found higher incidence among females [12].

Supracondylar fractures of humerus are classified using the Gartland classification, which also serves as a treatment guide [13]. Gartland types I and IIa fractures may be managed nonoperatively whereas types IIb and III are treated operatively [14].

## Objective

To describe the patients' condition and to evaluate the treatment and outcomes

## Materials and Method

We retrospectively reviewed the records of 40 consecutive patients with 40 displaced, supracondylar fractures of the humerus treated between January 2019 and December 2020.

All patients received general anesthesia and underwent closed reduction of their fractures in the operating room of Alsalam and Al-Durrah hospital, in Aden.

The fractures were stabilized with III lateral K-wires fixation or with two crossed K-wire fixation. The obtained data were sex, age, side of injury, degree of swelling, time between injury and fixation, trial of reduction, time of removal of K-wires and complications.

The collected data were tabulated and statistical analysis was done by estimating rates, means and standard deviations, Fisher test was used and p-value < 0.05 was considered as statistically significant. The statistical software package SPSS version 17 was used.

## Results

Table 1 & Figure 1 reveal 40 patients were included in the study. Twenty-one (52.5%) of the patients were males and 19 (47.5%) were females. (Male : female ratio was 1.1 : 1). The age of the study patients ranged between 2 to 10 years and the mean age was  $6.6 \pm 2.1$  years. Twenty-four (60%) patients had the fracture on the right arm, and 16 (40%) patients had the fracture on the left arm. Table 1 & Figure 2 also, show the degree of swelling and there were 16 (40%) moderate, 14 (35%) mild and 10 (25%) severe. Generally, all the study patients underwent surgery within 24 hours of injury: 16 (40%) cases within less than 6 hours, 19 (47.5%) cases between 6 and 12 hours and 5 (12.5%) cases between >12 and 24 hours after injury. The mean time was  $8.1 \pm 4.5$  hours. There were 11 (27.5%) cases of once trial reduction, 14 (35%) of twice trial reduction and 15 (37.5%) of three times trial reduction.

Most supracondylar fractures of the humerus recovered at the final follow up which was between 3 to 4 months. The average removal of K-wires was 3.55 weeks. Twenty-six (65%) patients were treated by III lateral K-wires fixation and 14 (35%) were treated by crossed K-wire fixation (Table 1 & Figure 2).

Table 1: Distribution of variables of the study patients (n=40)

Variables	No	%
Sex:		
Males	21	52.5
Females	19	47.5
Male to female ratio:	1.1:1	
Mean age (years):	6.6 ± 2.1	
Age range (years):	2 - 10	
Side involved:		
Right	24	60
Left	16	40
Degree of swelling:		
Mild	14	35
Moderate	16	40
Severe	10	25
Time b/w injuries and fixation:		
Less than 6 hours	16	40
6 – 12 hours	19	47.5
> 12 - 24 hours	5	12.5
Mean timing of reduction (hours)	8.1 ± 4.5	
Trial of reduction:		
Once	11	27.5
Twice	14	35
Three	15	37.5
Range of removal time K-wires (weeks):	3 – 4	
Average removal of K-wires (weeks):	3.55	
Method of fixation:		
III lateral	26	65
Cross	14	35

Figure 1: Distribution of study patients' related to sex(n=40)

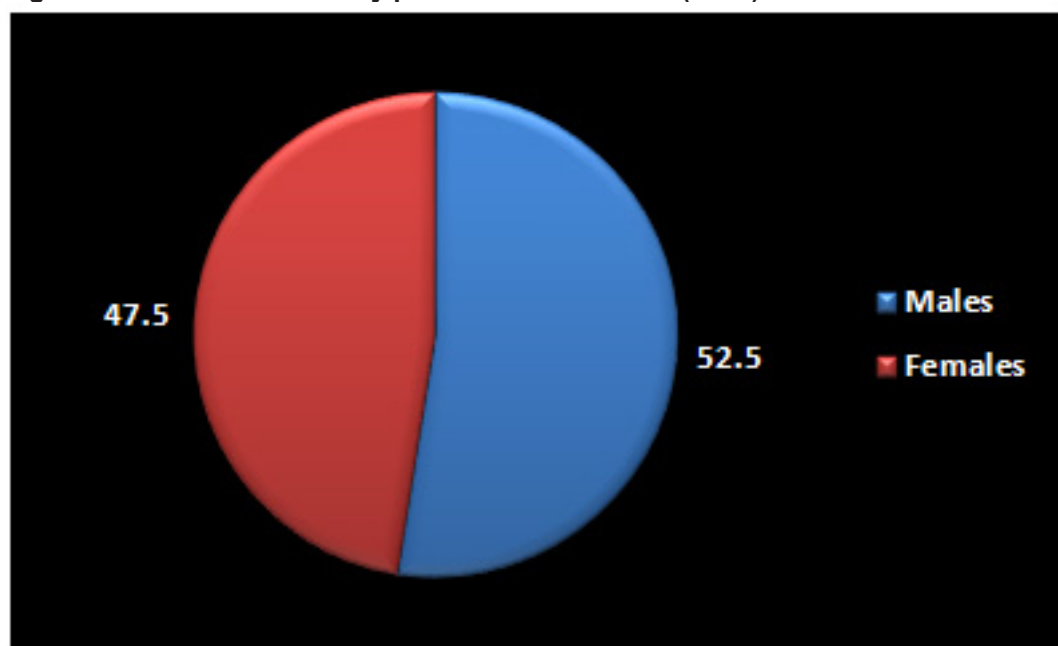
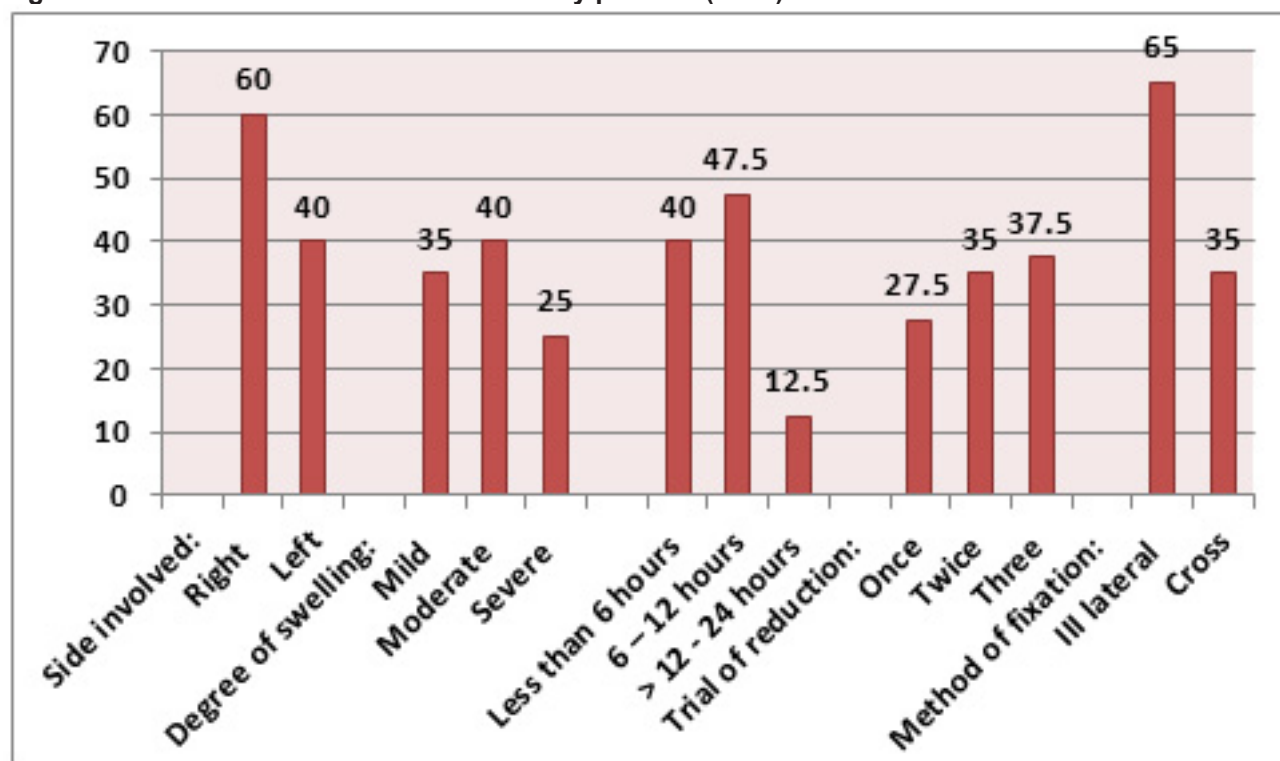


Figure 2: Distribution of variables of the study patients (n=40)



Post-operatively, 7 (17.5%) patients got neuropraxia in the crossed K-wire group (n = 14), and none in the lateral K-wire group. Two (5.0%) patients got angulation, one in the crossed K-wire group (n = 14), and one in the III lateral K-wire group (n = 26). There were 2 (5.0%) coronal displacement in the patients treated by inserting III lateral K-wires. Comparison between the two groups were found statistically significant (p = 0.000), as shown in Table 2 & Figure 3.

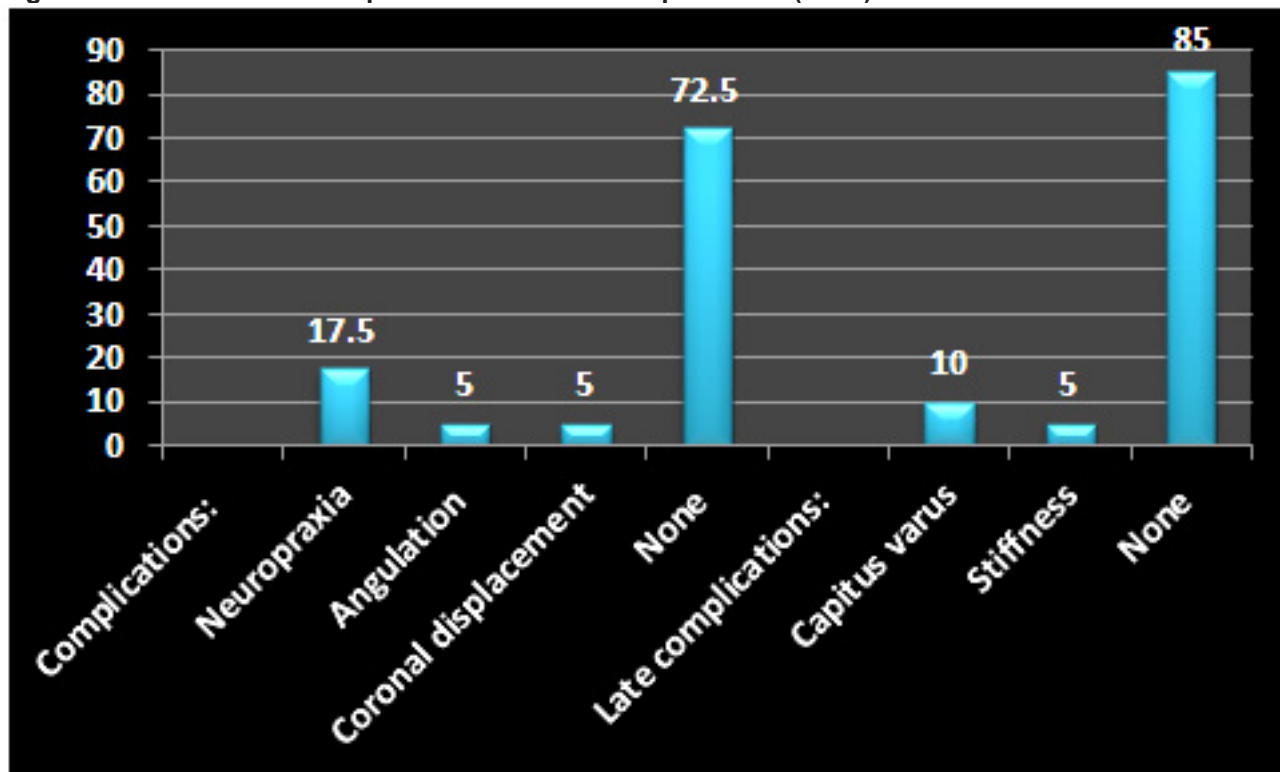
Late complications were found in 6 patients. Cupitus varus was seen in 4 patients, 2 (5.0%) in the crossed K-wire group and 2 (5.0%) in the III lateral K-wire group.

Stiffness was found in the III lateral K-wire group with 2 (5.0%) patients, Comparison between the two groups was found not statistically significant (p > 0.05), (Table 2 & Figure 3).

Table 2: Distribution of complications related to method of fixation (n=40)

Variables	Method of fixation		Total		P-value	
	Cross	III Lateral	Total			
	No	(%)	No	(%)	No	(%)
<b>Complications:</b>						
Neuropraxia	7	(17.5)	0	(0.0)	7	(17.5)
Angulation	1	(2.5)	1	(2.5)	2	(5.0)
Coronal displacement	0	(0.0)	2	(5.0)	2	(5.0)
None	6	(15.0)	23	(57.5)	29	(72.5)
<b>Total</b>	14	(35.0)	26	(65.0)	40	(100)
<b>Late complications:</b>						
Cupitus varus	2	(5.0)	2	(5.0)	4	(10.0)
Stiffness	0	(0.0)	2	(5.0)	2	(5.0)
None	12	(30.0)	22	(55.0)	34	(85.0)
<b>Total</b>	14	(35.0)	26	(65.0)	40	(100)

Figure 3: Distribution of complications and late complications (n=40)



## Discussion

Supracondylar fractures of the humerus are the most common elbow injuries in children and make up approximately 60% of all elbow injuries in the first decade of life [15]. These injuries can be one of the most difficult to treat, owing to the presence of associated immediate and late complications like compartment syndrome, neurovascular damage, Volkman's ischaemic contracture and malunion [16,17].

Oetgen et al [18] recommended in their study the necessity of early treatment in order to avoid complications, as a result, routine surgical management for any sort of fracture with displacement.

In our present study, the total study patients were 40. Twenty-one (52.5%) of the patients were males and 19 (47.5%) were females. (Male : female ratio was 1.1 : 1). The age of the patients ranged between 2 to 10 years and the mean age was  $6.6 \pm 2.1$  years. In addition the fractures were 16 (40%) left-sided and 24 (60%) right-sided fractures. Regarding the sex, age of children and sides of fracture, our results are similar to some reported studies [19,20] and differed from the results reported in other studies [21-23]

In this study, the degree of swelling was as follows: 16 (40%) moderate, 14 (35%) mild and 10 (25%) severe. Generally, all the study patients underwent surgery within 24 hours of injury: 16 (40%) cases within less than 6 hours, 19 (47.5%) cases between 6 and 12 hours and 5 (12.5%) cases between >12 and 24 hours after injury. The mean time was  $8.1 \pm 4.5$  hours.

Sadek et al [20] from Egypt reported similar to our finding that the operations were done within the first 24 hours after admission.

We found in our study post-operatively, 7 (17.5%) patients got neuropraxia in the crossed K-wire group (n = 14), and none in the III lateral K-wire group.

Lee et al [24] mentioned that in lateral wire fixation, divergent wires have been shown to be more stable in extension and varus loading than crossed wires but not in valgus. There are reports of clinical failures of laterally placed wires, thought to be due to poor technique in reduction and fixation [25]. Reports vary as to the loss of reduction using lateral wires. The systematic review by Brauer et al [26], observed that the probability of deformity, from loss of position, was 0.58 times lower with medial/lateral crossed wires than with lateral entry wires.

Studies have shown an increased incidence of iatrogenic nerve injury when a medial wire is used [27]. Skaggs et al [28] observed no loss of reduction when comparing two groups using crossed wires and lateral wires. There was an increased incidence of iatrogenic nerve injury in 17 out of 160 (10.6%) cases treated with a medial wire. Data pooled from 1,455 patients found that the incidence of ulnar nerve iatrogenic injury was 5.04 times higher in medial/lateral wire fixation compared to lateral entry fixation [26]. There is also concern about delayed iatrogenic nerve injury using medial wires [29].

Neural injuries can occur in 6.5% to 19% of cases of displaced supracondylar fractures and they are exceptional in non-displaced supracondylar fractures [30]. They can appear either before surgery (primary lesion) or after

reduction and fixation of the fracture (secondary lesion). Primary lesions are caused by fracture displacement, which can stretch, entrap or disrupt the nerve. Secondary lesions are caused by excessive manipulation, immobilization in hyperflexion or iatrogenic injuries by fixation [31,32].

In our study, two (5.0%) patients got angulation, one in the crossed K-wire group (n = 14), and one in the III lateral K-wire group (n = 26). Also, late complications were found in 6 patients with stiffness and cubitus varus. Cubitus varus were seen in 4 patients, 2 (5.0%) in the crossed K-wire group and 2 (5.0%) in the III lateral K-wire group. The stiffness was found in the III lateral K-wire group with 2 (5.0%) patients,

Bodycondylar angle measured after the surgery shows flexion or extension displacement of the distal fracture fragment. This angle changes during skeletal maturation. Body-condylar angle changes are related with extension degrees of the elbow [33]. Aslan et al [34] reported that the most common complication of pediatric supracondylar fractures is cubitus varus. D'Ambrosia [35] revealed that cubitus varus is very rare after an adequate reduction and is related with medial angulation of the distal fragment. Ippolito et al [36] state that varus deformity is due to the defect of the distal humeral epiphysis growth plate. Surgical intervention decreases the rate of varus deformity. Gosens and Bongers [37] reported a cubitus varus rate of 2.5 %.

## Conclusion

It can be concluded that the delay in surgical treatment may cause a number of complications. The choice of surgical approach should be based on the characteristics of fracture and the experience of the surgeon in surgical treatment of displaced supracondylar fractures in children.

## References

- Otsuka NY, Kasser JR. Supracondylar fractures of the humerus in children. *J Am Acad Orthop Surg.* 1997; 5: 19-26.
- Dimeglio A. Growth in pediatric orthopaedics. *J Pediatr Orthop.* 2001;21: 549-555.
- Cheng JC, Ng BK, Ying SY, et al. A 10-year study of the changes in the pattern and treatment of 6 493 fractures. *J Pediatr Orthop.* 1999; 19: 344-350.
- Otsuka NY, Kasser JR. Supracondylar fractures of the humerus in children. *J Am Acad Orthop Surg.* 1997;5:19-26.
- Lu D, Wang T, Chen H, Sun LJ. Management of pin tract infection in pediatric supracondylar humerus fractures: a comparative study of three methods. *Eur J Pediatr.* 2017;176(5):615-20.
- Piskin A, Tomak Y, Sen C, Tomak L. The management of cubitus varus and valgus using the Ilizarov method. *J Bone Joint Surg Br.* 2007;89:1615-9.
- Otsuka NY, Kasser JR. Supracondylar fractures of the humerus in children. *J Am Acad Orthop Surg.* 1997;5(1):19-26.
- Omid R, Choi PD, Skaggs DL. Supracondylar humeral fractures in children. *J Bone Joint Surg [Am]* 2008; 90-A(5):1121-1132.
- Morris S, McKenna J, Cassidy N, McCormack. Elbow injuries in paediatric population : Fractures of the distal humerus. *Irish J Orthop Surg Trauma.* 2001; 6: 31-38.
- Cheng JC, Lam TP, Maffulli N. Epidemiological features of supracondylar fractures of the humerus in Chinese children. *J Pediatr Orthop B.* 2001;10:63-67]
- Farnsworth CL, Silva PD, Mubarak SJ. Etiology of supracondylar humerus fractures. *J Pediatr Orthop.* 1998;18:38-42.
- Houshian S, Mehdi B, Larsen MS. The epidemiology of elbow fracture in children: analysis of 355 fractures, with special reference to supracondylar humerus fractures. *J Orthop Sci.* 2001;6:312-315.
- Gartland JJ. Management of supracondylar fractures of the humerus in children. *Surg Gynecol Obstet.* 1959; 109:145-154.
- Parikh SN, Wall EJ, Foad S, et al. Displaced type II extension supracondylar humerus fractures: do they all need pinning? *J Pediatr Orthop.* 2004; 24: 380-384.
- Herring JA. Tachdjian's Pediatric Orthopaedics. 3rd ed. Vol. 3. Philadelphia: W.B. Sanders, Fracture about the elbow; 2002. pp. 2139-221.
- Ramachandran M, Skaggs DL, Crawford HA, Eastwood DM, Lanlode FD, Vitale MG, et al. Delaying treatment of supracondylar fractures in children: has the pendulum swung too far? *J Bone Joint Surg Br.* 2008; 90(9):1228-33.
- Kruschemandl I, Aldrian S, Kottstorfer J, Seis A, Thalhammer G, Egkher A. Crossed pinning in paediatric supracondylar humerus fractures: a retrospective cohort analysis. *Int Orthop.* 2012; 36(9):1893-98.
- Oetgen M, Mirick G, Atwater L, Lovejoy J (2015) Complications and Predictors of Need for Return to the Operating Room in the Treatment of Supracondylar Humerus Fractures in Children. *The Open Orthopaedics J.* 2015; 9: 139-142
- Lucas Moratelli, Henrique Matias Santarosa, Angela Yuka Katayama, William Dias Belangero. Influence of time to surgery and pin fixation (lateral or crossed) on Flynn's criteria in Gartland type II and III supracondylar fracture: A retrospective study on 129 patients. *Journal of Musculoskeletal Surgery and Research.* 2019; (3&4): 342-345
- Sadek AA, Elsayed M, El-Azab HEM, Noamany HH. Comparison of Fixation of supracondylar humeral fractures in children by lateral cross-wiring technique versus traditional lateral pinning. *Sohag Medical Journal.* 2018; 22(1): 265-271
- Mohammed Bagir Al-Sharaa, Mohammed Shihab Al-Edanni. Functional outcome of closed reduction of supracondylar humerus fracture with cross Kirschner wire in children. *Rawal Medical Journal.* 2022; Vol. 47 (1): 137-140
- Xianglu Ji, Allieu Kamara, Enbo Wang, Tianjing Liu, Liwei Shi and Lianyong Li. A two-stage retrospective analysis to determine the effect of entry point on higher exit of proximal pins in lateral pinning of supracondylar humerus fracture in children. *Journal of Orthopaedic Surgery and Research.* 2019; 14:2-8

23. Mahmoud Abdel Karim, Ahmed Hosny, Nasef Mohamed Nasef Abdelatif, Mohamed Mahmoud Hegazy, Walid R. Awadallah, Sherif A. Khaled, Mostafa A. Azab, Walid A ElNahal, Hany Mohammady. Crossed Wires Versus 2 Lateral Wires in Management of Supracondylar Fracture of the Humerus in Children in the Hands of Junior Trainees. *J Orthop Trauma*. 2016; Volume 30 (4): e123-e128
24. Lee SS, Mahar AT, Miesen D, Newton PO. Displaced pediatric supracondylar humerus fractures: biomechanical analysis of percutaneous pinning techniques," *Journal of Pediatric Orthopaedics*. 2002; vol. 22(4): 440–443.
25. Skaggs DL, Cluck MW, Mostofi A, Flynn JM, Kay RM. Lateral-entry pin fixation in the management of supracondylar fractures in children. *Journal of Bone and Joint Surgery*. 2004; 86 (4): 702–707.
26. Brauer CA, Lee BM, Bae DS, Waters PM, Kocher MS. A systematic review of medial and lateral entry pinning versus lateral entry pinning for supracondylar fractures of the humerus. *Journal of Pediatric Orthopaedics*. 2007; 27(2): 181–186.
27. Stephen Paul Guy, Ramakrishna Rao Ponnuru, Sreenadh Gella, Nirmal Tulwa. Lateral Entry Fixation Using Three Divergent Pins for Displaced Paediatric Supracondylar Humeral Fractures. *ISRN Orthopedics*. 2011; 8: 1-5.
28. Skaggs DL, Hale JM, Bassett J, Kaminsky C, Kay RM, Tolo VT. Operative treatment of supracondylar fractures of the humerus in children: the consequences of pin placement. *Journal of Bone and Joint Surgery*. 2001; 83(5): 735–740.
29. Lyons JP, Ashley E, Hoffer MM. Ulnar nerve palsies after percutaneous cross-pinning of supracondylar fractures in children's elbows. *Journal of Pediatric Orthopaedics*. 1998; 18(1): 43–45.
30. Bashyal RK, Chu JY, Schoenecker PL, et al. Complications after pinning of supracondylar distal humerus fractures. *J Pediatr Orthop*. 2009; 29(7):704-708.
31. Gosens T, Bongers KJ. Neurovascular complications and functional outcome in displaced supracondylar fractures of the humerus in children. *Injury*. 2003; 34(4): 267-273.
32. Valencia M, Moraleda L, Díez-Sebastián J. Long-term functional results of neurological complications of pediatric humeral supracondylar fractures. *J Pediatr Orthop*. 2015; 35(6): 606-610.
33. Jones KG. Percutaneous pin fixation of fractures of the lower end of the humerus. *Clin Orthop Relat Res*. 1967; 50:53–69
34. Aslan A, Konya MN, Ozdemir A, Yorgancig H, et al. Open reduction and pinning for the treatment of Gartland extension type III supracondylar humeral fractures in children. *Strat Traum Limb Recon*. 2014; 9:79–88
35. D'ambrosia RD. Supracondylar fractures of humerus—prevention of cubitus varus. *J Bone Joint Surg*. 1972; 54A:60–66 37.
36. Ippolito E, Catenm R, Scola E. Supracondylar fractures of the humerus in children. *J Bone Joint Surg*. 1986; 68A:333–344 23.
37. Gosens T, Bongers KJ. Neurovascular complications and functional outcome in displaced supracondylar fractures of the humerus in children. *Injury*. 2003; 34:267–273 16.