

# Role of Endoscopic Sinus Surgery in Odontogenic Sinusitis

**Mohammed A. Alghamdi**

Surgery Department, Faculty of Medicine, Al-Baha University

**Correspondence:**

Dr. Mohammed A. Alghamdi

Otolaryngology Assistant Professor

Surgery Department, Faculty of Medicine, Al-Baha University

Saudi Arabia

**Email:** maaburas@bu.edu.sa

Received: December 2023. Accepted: January 2024; Published: February 1, 2024.

Citation: Mohammed A. Alghamdi. Role of Endoscopic Sinus Surgery in Odontogenic Sinusitis. World Family Medicine. February 2024; 22(2): 18-25. DOI: 10.5742/MEWFM.2024.95257024

## Abstract

Odontogenic sinusitis represents a distinct entity of sinusitis with a particular cause and unique microbiology. It has been reported that odontogenic sinusitis makes up to 40% of maxillary sinusitis and up to 70% of unilateral maxillary sinusitis. It requires a collaboration and multidisciplinary approach involving dental subspeciality and otolaryngology. Endoscopic sinus surgery plays an important role in many cases and in some instances, it delivers quicker improvement. In this paper, we present two cases where sinusitis of dental cause was treated with endoscopic sinus surgery.

**Keywords:** Endoscopic Sinus Surgery, Maxillary Sinusitis, Odontogenic Sinusitis, Acute Sinusitis, chronic sinusitis.

## Introduction

Paranasal sinuses comprise 4 pairs of mucosal-lined cavities in the skull draining to the nasal cavity(1). The maxillary sinus is pyramidal in shape measuring between 100-250 mm<sup>3</sup>. The posterior teeth apices lie close to the sinus floor (2). A variety of dental pathologies may cause sinusitis including periodontitis, oroantral fistula (OAF), or dental treatment-related foreign bodies(3). Odontogenic sinusitis (OS) accounts for 25-40% of all maxillary sinusitis and 70% of unilateral maxillary sinusitis (4). Dental-caused sinusitis may extend to affect the osteomeatal complex leading to the affection of ethmoid and frontal sinus. Endoscopic sinus surgery plays an important role in many cases allowing drainage of the infection through the natural ostium(5,6).

## Case 1

### Case Presentation:

A 34-year-old male, with a known case of hypertension, presented to the ENT clinic with a one-month history of nasal discharge and obstruction. Symptoms had commenced after left upper molar teeth extraction, progressively worsening with time. The nasal discharge was purulent, associated with postnasal drip, hyposmia, and facial heaviness, with no improvement after antibiotic therapy, patient also reported secretion from the site of extracted teeth. A thorough examination revealed hypertrophied inferior turbinate bilaterally, a mild deviation of the nasal septum to the left, and purulent discharge from the left osteomeatal complex, and Oroantral communication in the site of extracted teeth.

### Diagnostic Workup:

CT paranasal sinuses revealed bilateral deviated nasal septum and opacification of the left maxillary sinus and partial opacification of the anterior ethmoid and frontal sinus related to the obstruction of the osteomeatal complex. A bone defect was noticed at the site of extracted teeth (Fig. 1) and an apical radiolucency at the neighboring teeth (Fig. 2). The patient underwent left maxillary antrostomy and sinus wash with intraoperative findings confirming purulent discharge from the left maxillary sinus ostium. The procedure was well-tolerated.

### Postoperative Management:

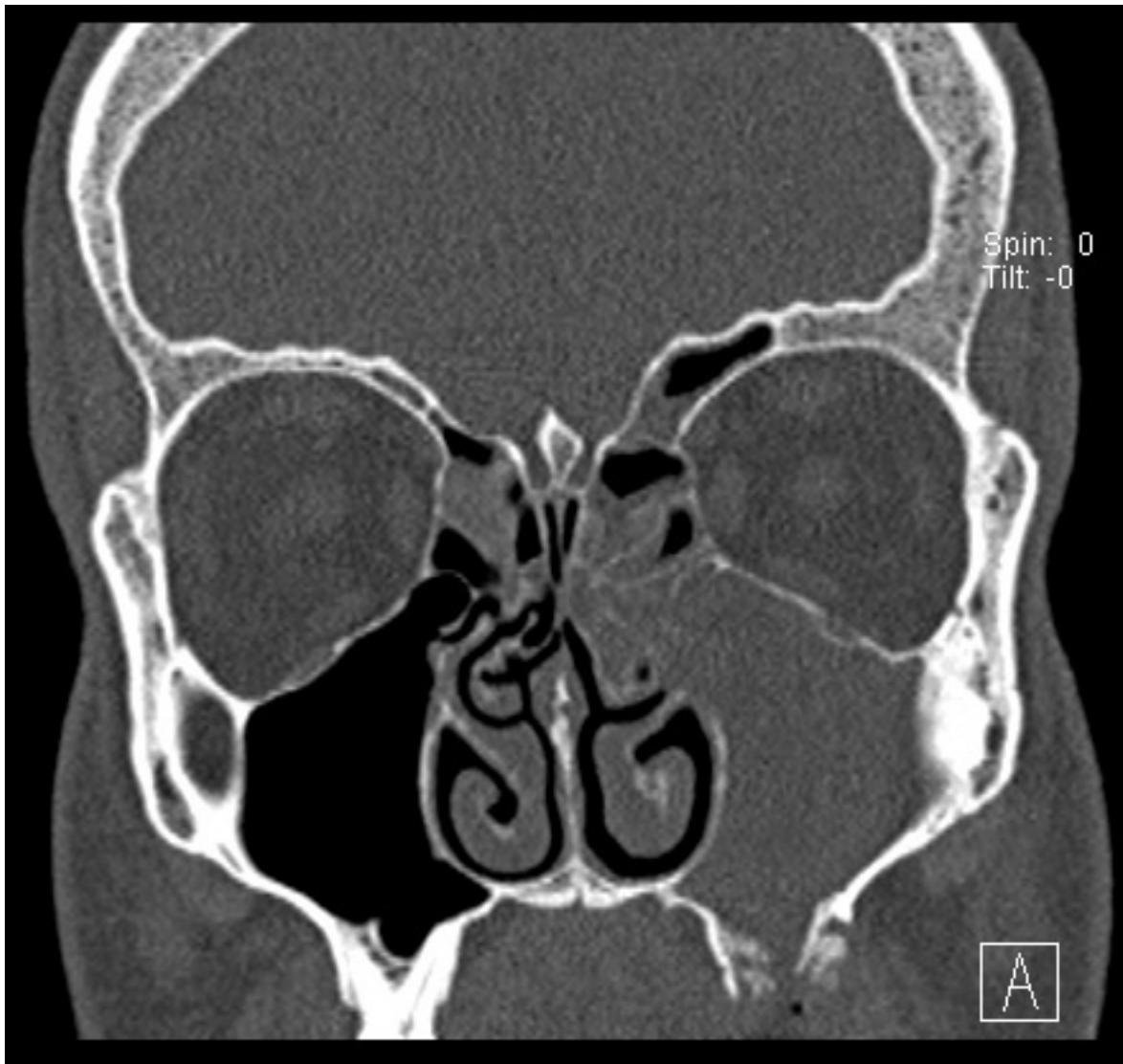
The patient received antibiotics and nasal wash. Postoperatively, he immediately reported improvement of the pressure feeling.

### Follow-up:

At one-week follow-up, the patient reported significant improvement in nasal obstruction and discharge. A nasal scope examination confirmed a clear left maxillary sinus with no evidence of purulent nasal discharge.

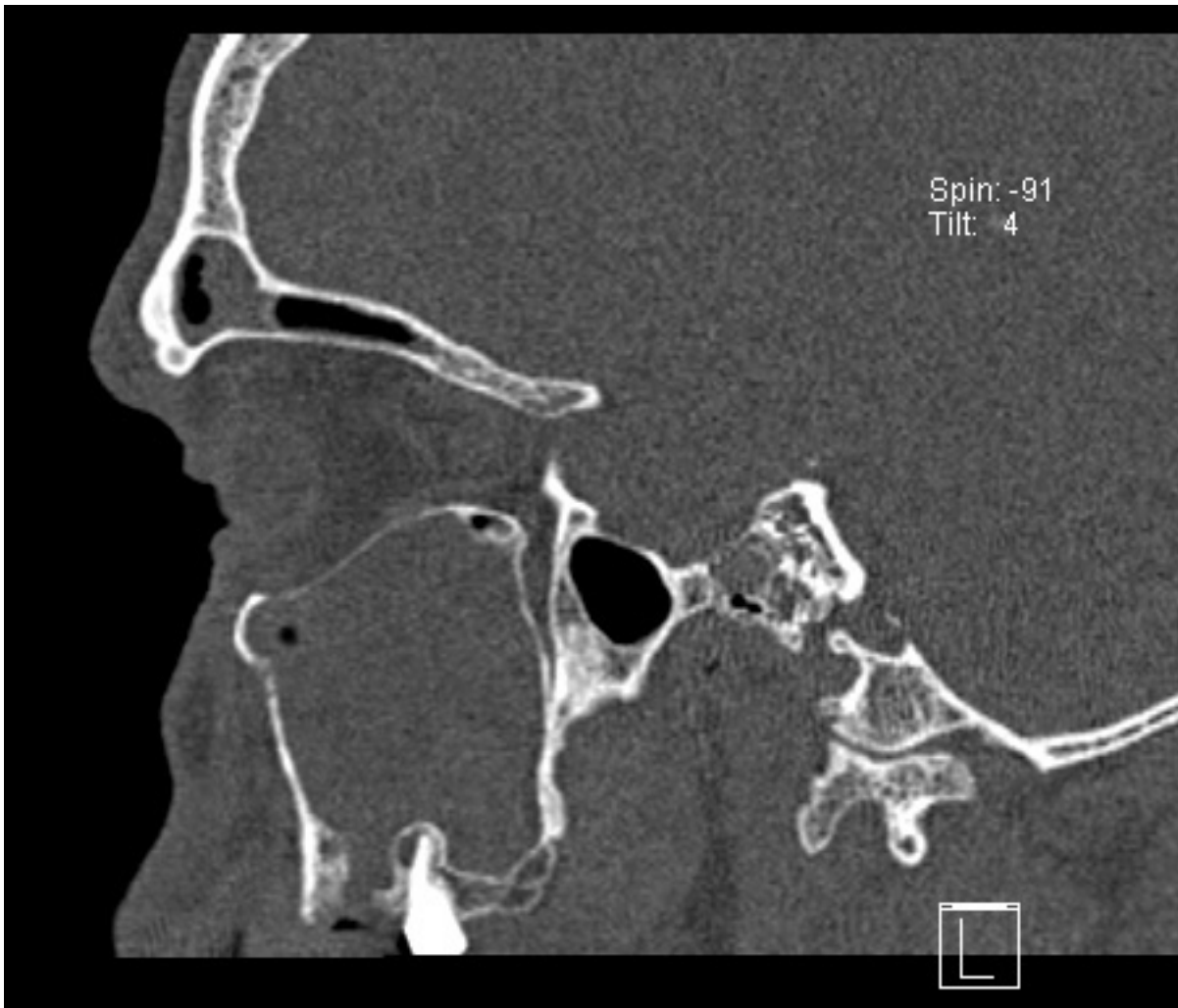
At three weeks of follow-up the patient had complete closure of the oroantral communication and was symptom-free. He was referred to his dentist to treat the neighboring teeth.

Case 1



**Figure 1: Coronal Section of CT scan showing left maxillary sinusitis with bony defect at the area of oronasal fistula**

## Case 1



**Figure 2: Maxillary sinusitis with oroantral fistula and periapical lesion on the neighboring teeth.**

## Case 2

### **Case Presentation:**

A 58-year-old female, known for diabetes mellitus, hypertension, dyslipidemia, hypothyroidism, and successfully treated hepatitis C, sought consultation at the ENT clinic due to persistent headaches and worsening nasal obstruction for two months following left upper molar teeth failed sinus lift and implant. Symptoms included purulent nasal discharge, postnasal drip, hyposmia, and facial heaviness. Despite prior antibiotic use, there was no improvement. On examination, there was mucosal congestion of the lateral nasal wall at the left side and purulent discharge at the middle meatus. The oral examination showed no sinus-oral communication.

### **Diagnostic Workup:**

Clinical examination revealed hypertrophied inferior turbinate bilaterally, mild deviation of the nasal septum to the right, and purulent discharge from the left osteomeatal complex. CT paranasal sinuses confirmed deviated nasal septum and obstruction of the osteomeatal complex with opacification of the left maxillary, anterior ethmoid, and frontal sinus and a bony defect at the previous dental procedure site (Fig. 3,4). The patient was planned for a left maxillary antrostomy.

### **Surgical Procedure:**

Intraoperative findings of purulent discharge from the left maxillary sinus ostium. The procedure involved uncinectomy, widening of the left maxillary nature ostium, irrigation, suctioning of the left maxillary sinus, and sinus wash. Successful evacuation of pus and debris related to possible contamination of the sinus from the previous dental procedure. The patient tolerated the procedure well.

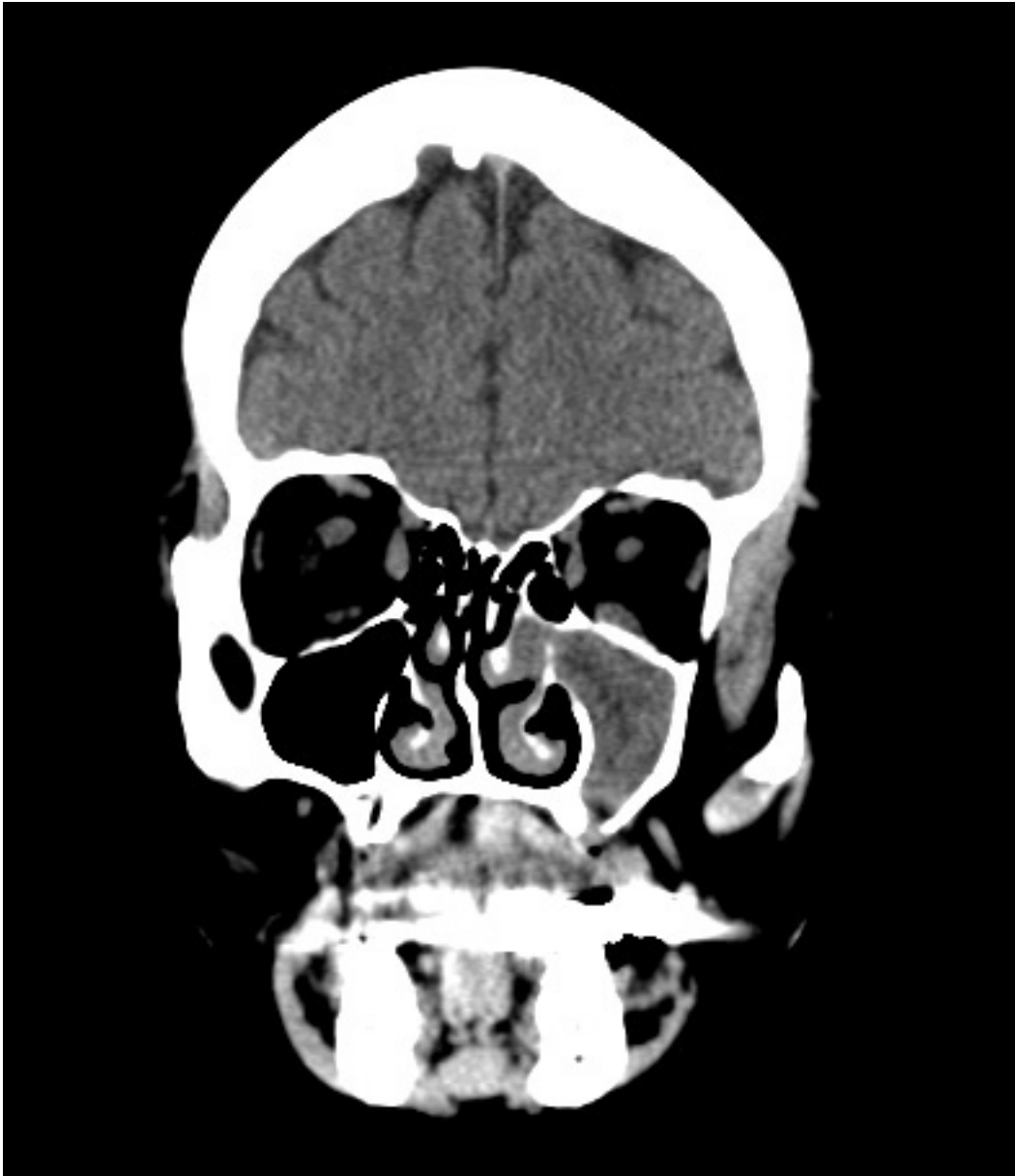
### **Postoperative Management:**

The patient received a course of oral antibiotics, and was instructed to continue nasal wash. In this case, the patient also reported immediate improvement of pressure feeling postoperatively.

### **Follow-up:**

At the one-week follow-up, the patient reported significant improvement in nasal obstruction and discharge. A nasal scope examination revealed a clear left maxillary sinus with no evidence of purulent nasal discharge.

## Case 2



**Figure 3: Coronal section showing unilateral opacification of the maxillary sinus and affection of osteomeatal complex with bony defect at sinus floor**

Case 2

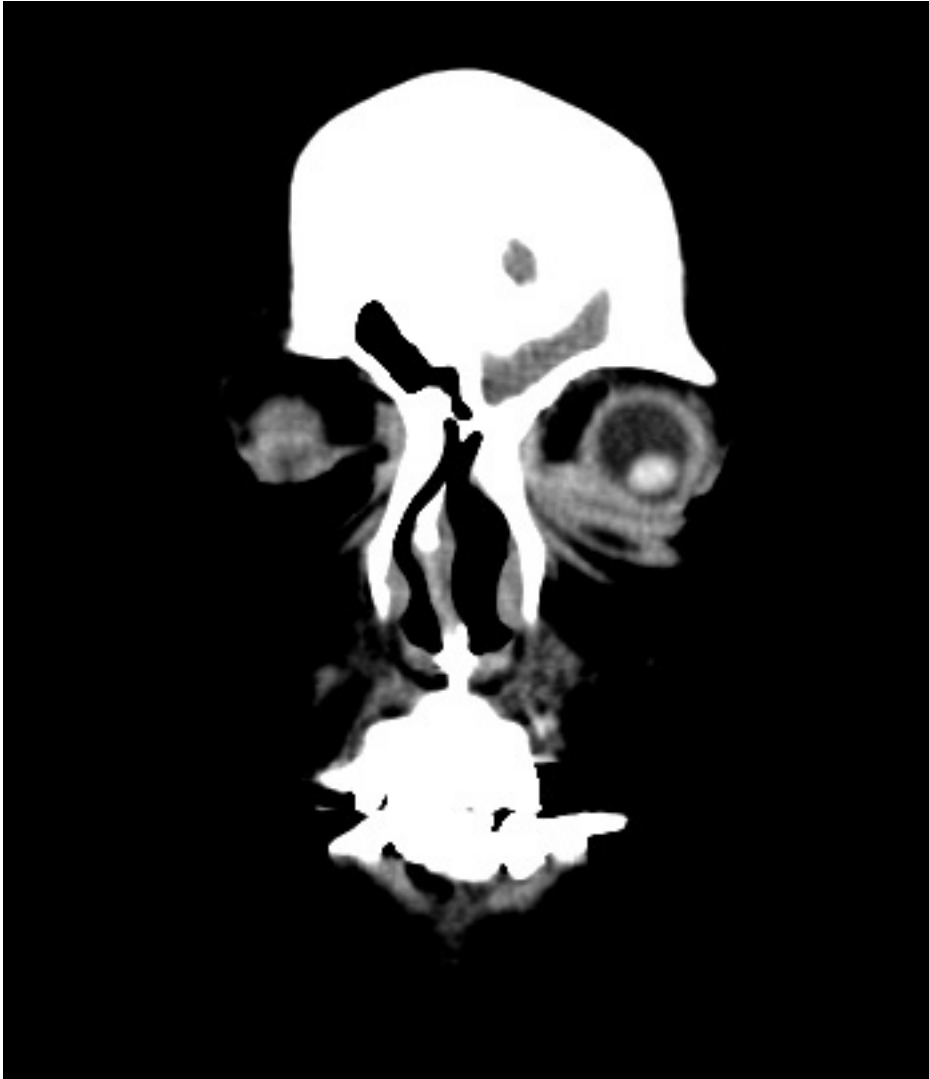

Figure 4: Coronal section showing opacification of the frontal sinus on the same side



## Discussion

The maxillary sinus is a pyramidal cavity located within the maxillary bone with a natural drainage pathway leading to the maxillary ostium. The Maxillary Ostium is part of the Osteomeatal complex which serves as a common drainage area for the maxillary, Frontal, and anterior ethmoid sinus(1,2). Teeth located in the alveolar process of the maxillary bone have intimate proximity to the sinus floor. A study demonstrated that in about 25 % of cases, the sinus floor extended to the level of teeth apices whereas in 10 % the floor even extended below the apices level(7). Dental Pathologies such as endodontic infection or dental procedures such as sinus lift or implant may cause maxillary sinusitis; this entity is termed odontogenic sinusitis (8,9). Odontogenic sinusitis is polymicrobial with a prevalence of anaerobic bacteria. 70% of isolates were susceptible to amoxicillin-clavulanate (2,10). It must be noted that high resistance to clindamycin has been reported making doxycycline the alternative of choice when treating penicillin-allergic patients(11). Patients with OS usually present with sinus complaints. In the majority of cases, evidence of dental pathology will be seen in radiological studies of the sinus but in about 35 % of the cases dental pathology can be proven only by clinical examination, hence a dental examination should be done if (OS) is suspected even if no pathology is seen on the radiological study (3,12). Endoscopic sinus surgery plays a vital role in managing OS, especially in cases where the osteomeatal complex is affected and subsequently other sinuses and in cases of sinusitis after dental implants (5,6,13–15). In our first case, the sinus surgery successfully improved the patient's symptoms and led to spontaneous closure of oroantral communication. In the second case, the patient failed to improve on antibiotic therapy; the surgery allowed drainage of pus material and possible contamination of the sinus related to previous dental procedure. In both cases, sinus surgery allowed immediate improvement of the symptoms.

## Conclusion

Odontogenic sinusitis is an entity that requires a multidisciplinary approach and good communication between the treating dentist, oral surgeon, and otolaryngologist. There are no clear guidelines for treatment and there is a lack of literature on this aspect when compared to the prevalence of the problem. Endoscopic sinus surgery plays a vital role in many cases, especially in cases with osteomeatal complex involvement.

## References

1. Anatomy, Head and Neck, Nose Paranasal Sinuses - StatPearls - NCBI Bookshelf [Internet]. [cited 2024 Jan 2]. Available from: <https://www.ncbi.nlm.nih.gov/books/NBK499826/>
2. Whyte A, Boeddinghaus R. The maxillary sinus: physiology, development and imaging anatomy. *Dentomaxillofacial Radiology*. 2019 Dec;48(8):20190205.
3. Craig JR, Tataryn RW, Cha BY, Bhargava P, Pokorny A, Gray ST, et al. Diagnosing odontogenic sinusitis of endodontic origin: A multidisciplinary literature review. *American Journal of Otolaryngology*. 2021 May;42(3):102925.
4. Craig JR. Odontogenic sinusitis: A state-of-the-art review. *World j otorhinolaryngol-head neck surg*. 2022 Mar;8(1):8–15.
5. Gâta A, Toader C, Valean D, Trombitaş VE, Albu S. Role of Endoscopic Sinus Surgery and Dental Treatment in the Management of Odontogenic Sinusitis Due to Endodontic Disease and Oroantral Fistula. *JCM*. 2021 Jun 19;10(12):2712.
6. Ye J, Hu S, Bian M, Yuan J, Tang J. Endoscopic sinus surgery plays an essential role in systematic treatment of odontogenic maxillary sinusitis. *Laparoscopic, Endoscopic and Robotic Surgery*. 2018 Jun;1(1):19–23.
7. Altaweel AA, Saad Sowairi SM, Saaduddin Sapri AM, Saeedi SA, Alamri AH, Alnobi AA, et al. Assessment of the Relationship between Maxillary Posterior Teeth and Maxillary Sinus Using Cone-Beam Computed Tomography. *Int J Dent*. 2022 Jul 5;2022:6254656.
8. Martu C, Martu MA, Maftei GA, Diaconu-Popa DA, Radulescu L. Odontogenic Sinusitis: From Diagnosis to Treatment Possibilities—A Narrative Review of Recent Data. *Diagnostics*. 2022 Jun 30;12(7):1600.
9. Sato K, Chitose S ichi, Sato K, Sato F, Ono T, Umeno H. Pathophysiology of current odontogenic maxillary sinusitis and endoscopic sinus surgery preceding dental treatment. *Auris Nasus Larynx*. 2021 Feb;48(1):104–9.
10. Saibene AM, Vassena C, Pipolo C, Trimboli M, De Vecchi E, Felisati G, et al. Odontogenic and rhinogenic chronic sinusitis: a modern microbiological comparison. *Int Forum Allergy Rhinol*. 2016 Jan;6(1):41–5.
11. Zirk M, Dreiseidler T, Pohl M, Rothamel D, Buller J, Peters F, et al. Odontogenic sinusitis maxillaris: A retrospective study of 121 cases with surgical intervention. *J Craniomaxillofac Surg*. 2017 Apr;45(4):520–5.
12. Pokorny A, Tataryn R. Clinical and radiologic findings in a case series of maxillary sinusitis of dental origin. *International Forum of Allergy & Rhinology*. 2013;3(12):973–9.
13. Allevi F, Fadda GL, Rosso C, Martino F, Pipolo C, Cavallo G, et al. Treatment of Sinusitis Following Dental Implantation: A Systematic Review and Meta-Analysis. *Am J Rhinol Allergy*. 2022 Jul;36(4):539–49.
14. Predictive factors in patients undergoing endoscopic sinus surgery for odontogenic sinusitis - PubMed [Internet]. [cited 2024 Jan 4]. Available from: <https://pubmed.ncbi.nlm.nih.gov/27028710/>
15. Psillas G, Papaioannou D, Petsali S, Dimas GG, Constantinidis J. Odontogenic maxillary sinusitis: A comprehensive review. *J Dent Sci*. 2021 Jan;16(1):474–81.