

# The manifestations of asthma in a child with Williams Syndrome

Hanaa Hamadallah

## Correspondence:

Dr Hanaa Hamadallah

Department of Pediatrics, Faculty of Medicine in Rabigh,  
King Abdulaziz University,  
Jeddah 80205, Saudi Arabia

**Email:** hhamdallah@kau.edu.sa

Received: March 2023. Accepted: April 2023; Published: May 1, 2023.

Citation: Hanaa Hamadallah. The manifestations of asthma in a child with Williams Syndrome. World Family Medicine. May 2023; 21(4): 49-52 DOI: 10.5742/MEWFM.2023.95256096

## Abstract

This case report introduces a 9-year-old girl with a known case of Williams Syndrome (WS) who presented with chronic dry cough to the pediatric pulmonologist clinic. The diagnosis of asthma was established based on detailed history, physical examination, and chest x-rays. She was treated with Budesonide nebulizer twice a day and Montelukast once daily. Afterwards, the patient had immediate clinical improvement. In reviewing the literature, we found that some individuals with WS had a history of asthma or wheezing. However, more research is needed to fully understand the exact relationship between the development of respiratory diseases and Williams Syndrome.

**Key words:** Williams syndrome, Asthma, Children

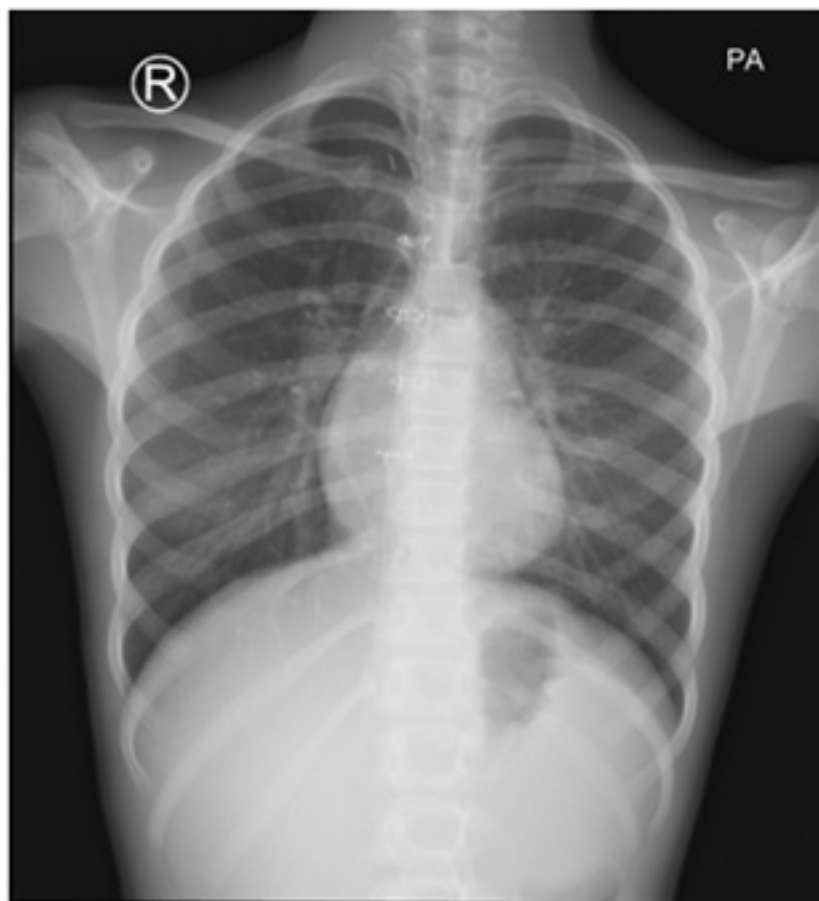
## Introduction

Williams syndrome (WS), also known as Williams Beuren Syndrome, is a rare genetic disorder that affects 1 in every 20,000 live births (1). Nearly all WS patients have a deletion of multiple genes including those codes for Elastin protein (ELN) that is located on the long arm of chromosome 7 (3-5). This mutation can be detected using the FISH method (Fluorescent In Situ Hybridization) (1). This syndrome has multiorgan involvement. Williams syndrome patients are characterized predominately by the unique dysmorphic face, congenital heart disease, endocrine problems such as hypercalcemia, growth retardation, cognitive disorders and other problems (1,2). However, having respiratory complications is not explored or investigated thoroughly. In this publication, we report on a female child with Williams syndrome who presented to the clinic with typical features of asthma.

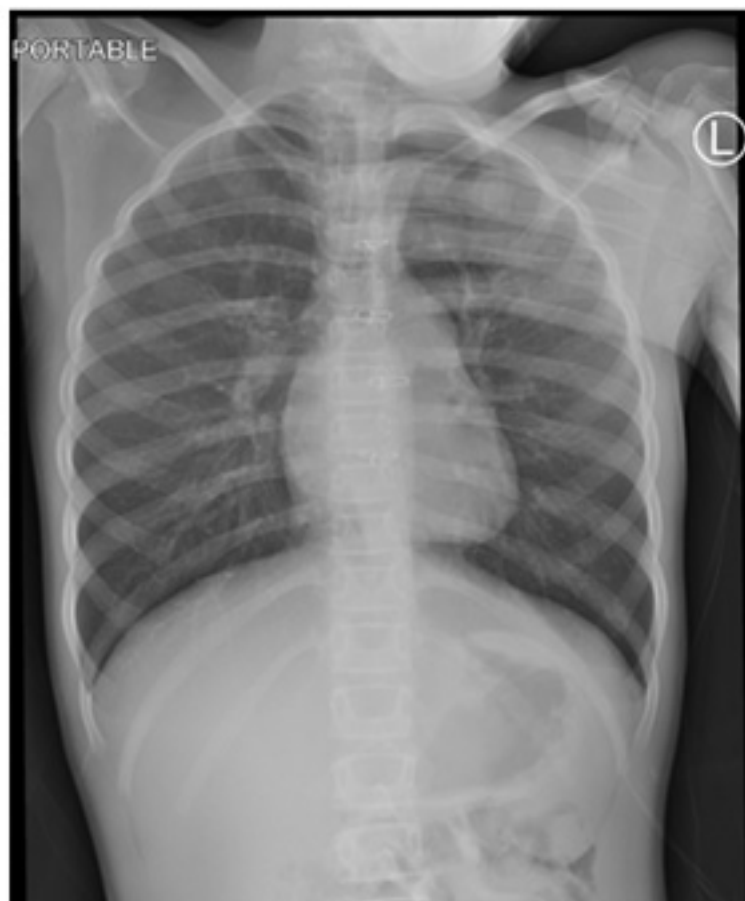## The Case

This report presents the case of a 9-year-old Jordanian girl with known case of Williams Syndrome who was referred from her pediatric cardiologist because of cough. She had a history of undiagnosed chronic cough for the last few months. This patient had a typical face with a broad forehead, periorbital puffiness, right ear deformity (microtia grade II), broad nasal tip, long philtrum, and a small chin. Although she is developmentally delayed, she can engage in conversations, complete full sentences and is very sociable. She was born at 37 weeks of gestation with a birth weight of 700 grams by emergency cesarean section due to placental abruption. She was admitted to NICU (Neonatal Intensive Care Unit) immediately after birth. Although the pregnancy was pre-booked, in the NICU the child was diagnosed with congenital heart disease (supra-aortic valvular stenosis) which was repaired in 2017 and Williams syndrome. She had a history of inguinal hernia repair as well at the age of 3 months. Both parents were in good health with no consanguinity and have five healthy siblings with no chronic diseases. Furthermore, there was a past medical history of multiple emergency visits due to cough and respiratory distress which was treated as an outpatient without an obvious diagnosis. The patient was referred to the pediatric pulmonologist clinic for undiagnosed chronic dry cough which was exacerbated the previous week after a viral infection. She was prescribed Budesonide 500 mcg nebulizer BID, Montelukast 5 mg OD and Mometasone nose spray 1 puff OD by her pediatric cardiologist and was advised to follow-up with the pediatric pulmonologist in the clinic.

The patient was seen in the clinic, and instantly the mother noticed major improvement after commencing the treatment. Although there is no family history of asthma, eczema or allergic rhinitis, the patient's cough was highly suggestive of asthma. Moreover, her chest x-ray showed hyperinflated lungs with no signs of infection. Her vitals were normal, and she was afebrile. Her examination revealed a child undernourished with Tanner stage B3, P2. Cardiac auscultation found a holosystolic murmur over aortic area and median sternotomy scar. Respiratory auscultation was normal with no added sounds and no chest deformity. The rest of the physical examination was normal. The mother was informed about the diagnosis of asthma and the need to continue the same treatment. A follow-up appointment was given in one month.



**Figure 1: Chest x-ray in April 2023 (one week after treatment).**



**Figure 2: Chest x-ray in March 2023 (before treatment).**

## Discussion

This paper discusses a case of Williams Syndrome that was referred to pediatric pulmonologist clinic for chronic cough. For evaluating the cause of the cough, a detailed history and physical examination were undertaken and complemented with chest x-rays. The chest x-rays that were done at the clinic (Figure 1) demonstrated surgical clips, and sternotomy wires. There was stable appearance on the cardiomeastinal silhouette, and the lungs were hyperinflated with mild central and upper lobe bronchial dilatation, more on the right side while the rest of the exam was unremarkable. Mild improvement was observed from the previous chest x-ray that was done a month before treatment (Figure 2).

Individuals with Williams Syndrome have genetic mutations for both genes coding elastin and LIM kinase enzymes due to their similar location on chromosome 7 (6). Elastin is an extracellular matrix and is the key component of tissue elasticity and elastic fibers in the lung parenchyma as well as the airway (7,13). It has been shown that “elastin is responsible for airway recoil, patency, and parenchymal tethering” (13). This could be a possible explanation wherefore patients with WS are at a higher risk of developing asthma and other obstructive lung diseases (12). A previous study has shown an association of elastin gene defect and increased risk of developing chronic obstructive lung disease and emphysema later in adulthood in patients with WS (7). Furthermore, another study demonstrated that elastin deficiency affects lung physiology negatively by increasing air trapping and airway obstruction emphasizing the importance of early monitoring of the lung functions when cases are adults (8).

Asthma is the most common chronic obstructive lung disease in children and is characterized by structural airway modifications. Asthma in Saudi Arabia affects approximately up to 33.7% of children (9). Wheezing, shortness of breath, dry cough and chest tightness were the usual clinical findings in asthmatic patients (10,11). Airway remodeling of airway smooth muscle (ASM) is the main pathophysiological modification that causes the signs and symptoms as well as decreases pulmonary functions (16). Several reports have shown that interaction between ASM and extracellular matrix proteins play a major role in airway remodeling in asthmatic patients (13-16).

The present case provides further support for the hypothesis that patients with WS are at a greater risk for developing pulmonary diseases, particularly asthma, since elastin insufficiency leads to negative effects on airway. Unfortunately, these results are limited by the lack of data particularly in young children. This could be due to the fact that exertion dyspnea is difficult to distinguish between cardiovascular and pulmonary causes without the appropriate investigations (7). On the other hand, cough and wheezing have been reported in adult patients with WS and they are less likely to overlap with possible cardiac causes (7).

Given the lack of reports on children, further work is required to explore the mechanism behind development of asthma in WS patients. Therefore, any patient with Williams Syndrome should have a routine pulmonary examination and monitoring of lung functions to avoid the development of chronic lung diseases.

## Conclusion

Although Williams Syndrome is a rare genetic disorder, it is well recognized among pediatricians with its characteristic features. Nevertheless, pulmonary manifestations are not well explored in patients with Williams Syndrome. Therefore, pulmonary evaluation early on is strongly suggested to avoid delayed diagnosis or the progression of lung diseases.

## References

- 1-Zamani H, Babazadeh K, Fattahi S, Mokhtari-Esbuie F. Williams-Beuren's Syndrome: A case report. *Case Reports in Medicine*. 2012;2012:1–4.
- 2- Morris CA. Williams Syndrome. 1999 Apr 9 [Updated 2017 Mar 23]. In: Adam MP, Mirzaa GM, Pagon RA, et al., editors. *GeneReviews®* [Internet]. Seattle (WA): University of Washington, Seattle; 1993-2023. Bookshelf URL: <https://www.ncbi.nlm.nih.gov/books/>
- 3-Wan ES, Pober BR, Washko GR, Raby BA, Silverman EK. Pulmonary function and emphysema in Williams-Beuren syndrome. *American Journal of Medical Genetics Part A*. 2010;152A(3):653–6.
- 4- Akimoto T, Suenaga J, Hayashi T, Hirokawa D, Ito S, Sato H, et al. Moyamoya syndrome in a patient with Williams Syndrome: A case report. *Pediatric Neurosurgery*. 2022;57(5):365–70.
- 5-Schubert C. The genomic basis of the Williams-Beuren syndrome. *Cellular and Molecular Life Sciences*. 2009;66(7):1178–97.
- 6-Kaplan P, Wang PP, Francke U. Williams (Williams Beuren) syndrome: a distinct neurobehavioral disorder. *Journal of Child Neurology*. 2001; 16(3):177–90.
- 7-National Center for Biotechnology Information (US). *Genes and Disease* [Internet]. Bethesda (MD): National Center for Biotechnology Information (US); 1998-. Williams syndrome. Available from: <https://www.ncbi.nlm.nih.gov/books/NBK22196/>
- 8-Kronquist EK, Kaur M, Gober LM, Knutsen RH, Fu Y-P, Yu Z-X, et al. Airflow obstruction in adults with Williams syndrome and mice with elastin insufficiency. *Diagnostics*. 2022;12(6):1438.
- 9-Alahmadi TS, Banjari MA, Alharbi AS. The prevalence of childhood asthma in Saudi Arabia. *International Journal of Pediatrics and Adolescent Medicine*. 2019;6(2):74–7.
- 10- Haktanir Abul M, Phipatanakul W. Severe asthma in children: Evaluation and management. *Allergology International*. 2019;68(2):150–7.
- 11-Kliegman R, Stanton B, St. Geme JW, Schor NF, Behrman RE. *Nelson textbook of pediatrics* (Edition 20.). Philadelphia, PA: Elsevier; 2016.
- 12- Reddel CJ, Weiss AS, Burgess JK. Elastin in asthma. *Pulmonary Pharmacology and Therapeutics*. 2012;25(2):144–53.
- 13-Turino GM. The lung parenchyma -a dynamic matrix. J. Burns Amberson lecture. *American Review of Respiratory Disease*. 1985;132:1324e34.
- 14-Burgess JK, Ceresa C, Johnson SR, Kanabar V, Moir LM, Nguyen TT, et al. Tissue and matrix influences on airway smooth muscle function. *Pulmonary Pharmacology and Therapeutics*. 2009;22:379e87.
- 15- Dekkers BG, Maarsingh H, Meurs H, Gosens R. Airway structural components drive airway smooth muscle remodeling in asthma. *Proceedings of the American Thoracic Society*. 2009;6:683e92.
- 16- Halwani R, Al-Muhsen S, Hamid Q. Airway remodeling in asthma. *Current Opinion in Pharmacology*. 2010;10:236e45.